

The Captain Morgan Technique for the Reduction of the Dislocated Hip

Gregory W. Hendey, MD, Arturo Avila, PA-C

From the University of California San Francisco-Fresno, Departments of Emergency Medicine (Hendey) and Orthopedic Surgery (Avila), Fresno, CA.

Study objective: We present our experience with a novel technique for the reduction of acute hip dislocation in the emergency department (ED).

Methods: We searched the medical records of all patients with a hip dislocation treated in our ED during a 4-year period. We recorded patient demographics, reduction technique, outcome and disposition, and whether the patient had a prosthetic hip. We reported characteristics of the entire study group and of the subset of patients for whom the Captain Morgan technique was used. Briefly, the technique involves placing the physician's knee behind the supine patient's flexed knee and lifting with anterior force, with rotation as needed.

Results: Of 77 patients meeting criteria, the mean age was 46 years (range 5 to 91 years), 35 (45%) had a prosthetic hip, and 67 (87%; 95% confidence interval 77% to 93%) received successful reduction in the ED. In 13 cases, the Captain Morgan technique was specifically described and was successful in 12 (92%; 95% confidence interval 64% to 100%). The single technique failure occurred in a patient with an acetabular fracture with an intra-articular fragment requiring open reduction. There were no described neurovascular complications or injuries to the knee.

Conclusion: We describe an interesting and novel technique for the reduction of a hip dislocation. Physicians should consider this method a primary technique for the acute management of hip dislocation in the ED. [Ann Emerg Med. 2011;58:536-540.]

Please see page 537 for the Editor's Capsule Summary of this article.

A **podcast** for this article is available at www.annemergmed.com.

0196-0644/\$-see front matter

Copyright © 2011 by the American College of Emergency Physicians.

doi:10.1016/j.annemergmed.2011.07.010

INTRODUCTION

Background

Reduction of a dislocation of the hip is an important emergency procedure. When dislocated from the acetabulum, the femoral head is at increasing risk of avascular necrosis as more time passes before reduction is accomplished. A number of reduction techniques have been described in the literature, but probably the best known and most widely used are the Allis and Bigelow techniques.^{1,2} Originally described in the late 1800s, these similar methods for the closed reduction of a hip dislocation involve flexing the supine patient's hip and knee to 90 degrees, lifting the lower leg to apply an anterior force to the hip, and then extending the leg while traction is continued. To effectively lift the patient's leg and apply sufficient force, many physicians straddle the patient by standing on top of the gurney,

Importance

Although these techniques are usually successful, they require substantial effort and expose the physician to the risk of lumbar strain or falling from the gurney. We propose a new technique,

which is a modification of a maneuver reported by Lefkowitz.³ We refer to it as the "Captain Morgan" technique because of the similarity to the familiar pose of the character in advertisements (Figure 1). The Captain Morgan technique allows the physician to remain standing on the floor while easily and safely applying the necessary force to the patient's hip to accomplish reduction.

Goals of This Investigation

The objective of this study was to describe the Captain Morgan technique of hip reduction and to describe patients for whom the method was used.

MATERIALS AND METHODS

Study Design

This was a retrospective cross-sectional study.

Setting and Selection of Participants

We searched the medical records database for hip dislocation patients (*International Classification of Diseases, Ninth Revision* code 835.xx) who were treated in the emergency department

Editor's Capsule Summary

What is already known on this topic

Common methods for reducing hip dislocations in the emergency department can place physicians at risk of injury.

What question this study addressed

This case series of 13 patients demonstrates success of the Captain Morgan technique (placing the physician's knee behind the supine patient's flexed knee and lifting with anterior force, with rotation as needed).

What this study adds to our knowledge

This maneuver appears to have an excellent success rate (>90%).

How this is relevant to clinical practice

The Captain Morgan procedure seems worth trying because it appears logistically easier than some techniques currently used.

(ED) at Community Regional Medical Center in Fresno, CA, during a 4-year period from January 1, 2007, through December 31, 2010. The center is a Level I trauma center with an annual ED census of 100,000 to 110,000 during the study and is home to the University of California San Francisco Fresno Emergency Medicine residency program. Most closed reductions are accomplished by residents or physician assistants supervised by emergency medicine attending physicians.

Methods of Measurement

Records were reviewed for the following inclusion criteria: acute hip dislocation, reduction attempt in the ED, and radiology reports demonstrating a hip dislocation. Patients could be included more than once, and both native and prosthetic hip dislocations were included. Cases were excluded if the encounter consisted of outpatient follow-up visit without an acute dislocation, if the diagnosis was incorrect, or records were missing or incomplete. All records were reviewed by one author (G.W.H.) with a standardized, paper data collection form that included demographics, technique, success or failure, hip prosthesis, and personnel involved. A research coordinator independently reviewed 10 charts to assess interrater reliability.

The Captain Morgan technique of hip reduction is a modification of a technique originally described by Lefkowitz³ in 1993. In the original description, the patient is supine, with the hip and knee flexed to 90 degrees. The physician places his or her knee behind the patient's knee and, using the knee as a fulcrum, applies anterior force to the hip by pushing downward on the ankle. In our modified technique, the patient is placed supine on a backboard on the gurney, which allows the use of a

strap to fix the patient's pelvis to the board and provides a solid footing for the physician. In fact, many patients arrive by ambulance in just this position. Next, we emphasize keeping the patient's knee flexed by placing one hand to hold the ankle down and the other behind the knee rather than using leverage to generate force. Anterior force is applied to the hip by lifting the patient's leg through a combination of plantar-flexion of the physician's ankle (stepping up on toes), and lifting with the hand behind the knee (Figure 1) (see video at <http://www.annemergmed.com>). Finally, if the reduction is not easily accomplished with sustained lifting anterior force, the physician should apply internal and external rotation, adduction, and abduction to the hip during traction by gently rocking and rotating the patient's lower leg.

Primary Data Analysis

Data were entered into a password-protected spreadsheet (Microsoft Excel 2008 for Mac, version 12.2.8; Microsoft, Redmond, WA). Descriptive statistics were calculated, along with 95% confidence intervals (CIs), using online calculators (<http://www.graphpad.com/quickcalcs>). κ was calculated to measure interrater reliability. The study was approved by the hospital institutional review board.

RESULTS

The medical records search revealed 167 potential cases during the study period. However, 73 were excluded because the encounter consisted of an outpatient follow-up visit rather than an acute dislocation in the ED. Another 17 were excluded for incorrect diagnoses, including fracture, arthritis, or congenital dislocation. Therefore, the final study population consisted of 77 cases in 61 patients with a hip dislocation and reduction attempts in the ED (Figure 2). The interrater agreement between 2 chart reviewers was 93%, with a κ of 0.86. Disagreements were resolved by a third review for consensus.

Forty (52%) of the patients were men, and 35 (45%) cases occurred in patients with a prosthetic hip. The mean age was 46 years, with a range of 5 to 91 years. Overall, 67 patients (87%; 95% CI 77% to 93%) underwent successful closed reduction in the ED. In 9 cases, the reduction was accomplished in the operating room either by closed reduction under general anesthesia or by open reduction, and 1 patient had a chronic, persistent dislocation that was not reduced. In 13 cases, the described method of reduction was the Captain Morgan technique. A different technique was described in 12 cases, and in 52 cases, the description was not sufficient to determine the technique used (Figure 2).

The success rate of the Captain Morgan technique was 12 of 13 cases (92%; 95% CI 64% to 100%). Eight of the patients had a prosthetic hip (62%). Reductions were performed by 9 emergency medicine residents (2 residents reduced 2 cases), 1 physician's assistant, and 1 emergency medicine attending physician. They were supervised by 8 emergency medicine attending physicians (one supervised 2 cases and one supervised 5). The single case of failed reduction occurred in a 41-year-old woman who fell while

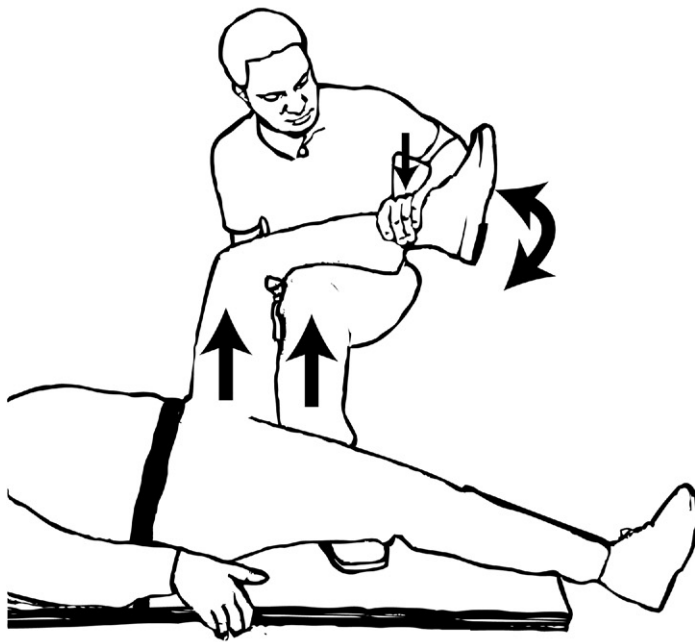


Figure 1. The patient is placed supine on a gurney, and the pelvis is fixed to a backboard with a strap. The patient's hip and knee are flexed to 90 degrees. The physician places one foot on the board, with a knee behind the patient's knee. The physician holds the patient's knee in flexion by holding the ankle down and applies an upward force to the hip by lifting with his or her calf and then gently rotates lower leg. Captain Morgan reproduced with permission from Diageo PLC.

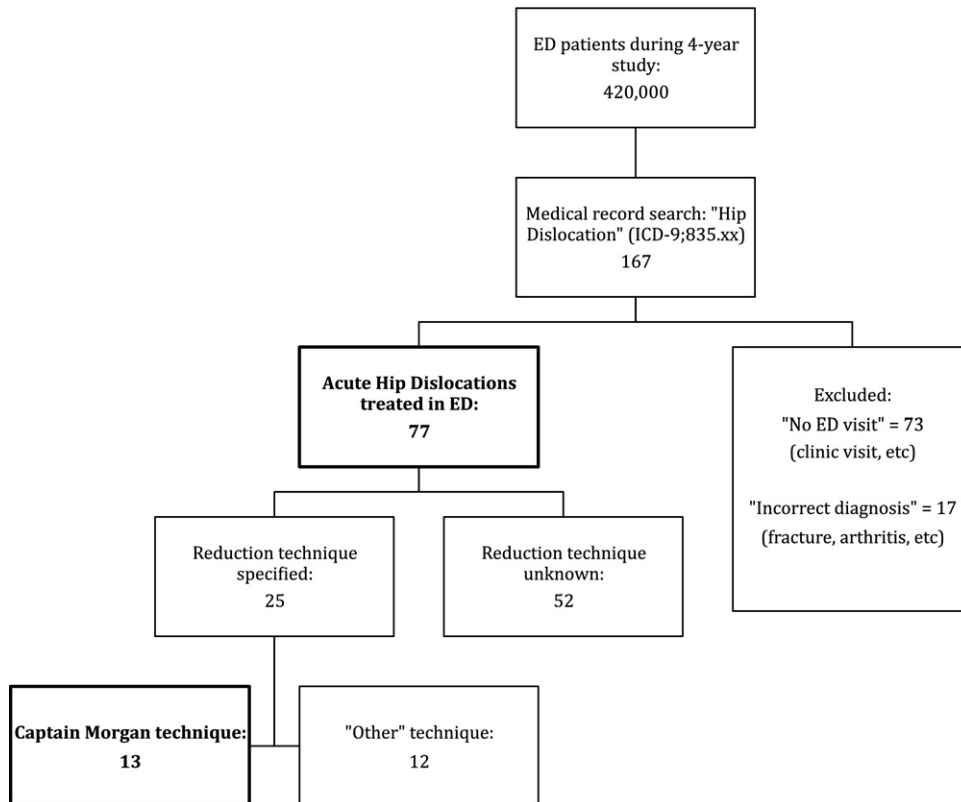


Figure 2. Flow chart of patients from total ED visits to patients with an acute hip dislocation treated in the ED with the Captain Morgan technique.

Table. Characteristics of hip dislocation patients treated with the Captain Morgan reduction technique.

Age/Sex	Mechanism of Injury	Direction	Fracture	Prosthesis	Success
61/F	Fall	Posterior	No	Yes	Yes
61/F	Rolled in bed	Superior/posterior	No	Yes	Yes
53/F	Twisted in chair	Superior/posterior	No	Yes	Yes
53/F	Sat on bed	Superior/posterior	No	Yes	Yes
18/M	Motorcycle accident	Superior/posterior	No	No	Yes
41/F	Roller skating	Anterior	Yes	No	No (see text)
60/M	Standing up	Superior/posterior	No	Yes	Yes
25/M	Motor vehicle crash	Superior/posterior	No	No	Yes
28/M	Auto versus pedestrian	Posterior	No	No	Yes
84/F	Fall from bed	Superior/lateral	No	Yes	Yes
18/M	Motor vehicle crash	Posterior	No	No	Yes
83/F	Bending over	Superior/posterior	No	Yes	Yes
66/F	Walking dog	Posterior/lateral	No	Yes	Yes

F, Female; M, male.

roller skating and sustained an anterior hip dislocation with an acetabular fracture (Table). After unsuccessful closed reduction in the ED, she was taken to the operating room for open reduction and internal fixation, where she was found to have an intra-articular bony fragment. Her course progressed well, and she was discharged in 3 days for physical therapy.

In all cases, postreduction radiographs were performed and no postreduction fractures were detected. Also, there were no documented neurovascular injuries or knee injuries associated with the reduction procedure. The majority of patients were reduced with procedural sedation and discharged from the ED.

LIMITATIONS

There are a number of limitations to this report. First, it is not a comparison of techniques to demonstrate the superiority of one over another. Many other techniques have been described, and we are unable to report whether our technique is faster, easier, or more successful or has fewer complications than others.⁴⁻¹⁰ This is merely a description of an easy technique used effectively in a series of patients. Second, it is likely that we excluded many cases in which the Captain Morgan technique was used because it was not adequately described in the medical record. It is a popular technique in our ED that is used commonly, but cases were included only if the technique was specifically described. Descriptions such as "successfully reduced with traction" were considered inadequate, and unfortunately most descriptions were vague. Thus, we may have missed many cases in which the technique was used. If all 8 cases of unsuccessful reduction with unknown technique actually used the Captain Morgan technique, the success rate could have been as low as 57%. Third, although there were no cases of fracture or injuries resulting from the reduction technique, it is difficult to conclude from our chart review that no subtle injuries occurred or were missed because of bias of an unblinded reviewer. Fourth, we cannot comment on the usefulness of the technique for the less common anterior dislocation because the majority of our cases were thought to be posterior. In fact, our single case of technique failure occurred in the presence of an anterior fracture-dislocation. Finally, because the number of cases is few, we cannot exclude the possibility of rare adverse events

such as fracture, neurovascular injury, or damage to the knee, and we cannot perform subgroup analyses to determine whether there are differences for older versus younger patients or for native versus prosthetic hips.

DISCUSSION

We described a series of cases successfully treated with a technique that should be useful to the emergency physician or orthopedic surgeon treating patients with a hip dislocation. The Captain Morgan technique allows the physician to apply a great deal of anterior force to the patient's hip in a controlled manner, with the patient supine on the gurney and the physician standing on the floor. Furthermore, we believe the modified method poses less risk of knee injury to the patient because the dominant force is applied by lifting the leg rather than through applying leverage at the knee. This positioning also allows the safe administration of sedation, which is frequently required for large joint dislocations, and it may reduce the risk of injury to the physician. Although the traditional methods to fix the patient's pelvis to the gurney include tying a sheet around the pelvis and gurney or asking an assistant to hold the pelvis down, the advantage of using a backboard and strap cannot be overemphasized.

As noted earlier, we cannot report that our method is superior to others, but it worked well for patients in our study, including those with first-time or recurrent dislocations and those with native or prosthetic hips. Future studies should focus on comparing this technique with others with respect to safety, ease of reduction, success rate, and complications.

In conclusion, we present an interesting and novel technique for the reduction of a hip dislocation. Physicians should consider this method a useful technique in the acute management of hip dislocation in the ED.

The authors acknowledge Diageo PLC for permission to use the Captain Morgan name and image, and Francis Fung for illustrating Figure 1.

Supervising editor: Judd E. Hollander, MD

Author contributions: GWH and AA conceived the study, designed the trial, and contributed substantially to article revision. GWH supervised the conduct of the trial and data collection; undertook data collection, management, and analysis; provided statistical advice on study design; and drafted the article. GWH takes responsibility for the paper as a whole.

Funding and support: By *Annals* policy, all authors are required to disclose any and all commercial, financial, and other relationships in any way related to the subject of this article as per ICMJE conflict of interest guidelines (see www.icmje.org). The authors have stated that no such relationships exist.

Publication dates: Received for publication June 2, 2011. Revision received June 30, 2011. Accepted for publication July 8, 2011. Available online August 12, 2011.

Address for correspondence: Gregory W. Hendey, MD, E-mail ghendey@fresno.ucsf.edu.

REFERENCES

1. Allis OH. *An Inquiry Into the Difficulties Encountered in the Reduction of Dislocations of the Hip*. Philadelphia, PA: Dornan Printer; 1896.
2. Bigelow HJ. On the dislocated hip. *Lancet*. 1878;1:860-862.
3. Lefkowitz M. A new method for reduction traumatic dislocations. *Orthop Rev*. 1993;2:253-256.
4. Dahnert LE, Hundley JD. Reduction of posterior hip dislocations in the lateral position using traction-countertraction: safer for the surgeon? *J Orthop Trauma*. 1999;13:373-374.
5. Howard CB. A gentle method of reducing traumatic dislocation of the hip. *Injury*. 1992;23:481-482.
6. Nordt WE. Maneuvers for reducing dislocated hips. *Clin Orthop Relat Res*. 1999;360:160-164.
7. Schafer SJ, Anglen JO. The East Baltimore lift: a simple and effective method for reduction of posterior hip dislocations. *J Orthop Trauma*. 1999;13:56-57.
8. Skoff HD. Posterior hip dislocation, a new technique for reduction. *Orthop Rev*. 1986;15:405-409.
9. Stefanich RJ. Closed reduction of posterior hip dislocation: the Rochester method. *Am J Orthop (Belle Mead NJ)*. 1999;28:64-65.
10. Yang E, Cornwall R. Initial treatment of traumatic hip dislocations in the adult. *Clin Orthop Relat Res*. 2000;377:24-31.

Did you know?

You can save your online searches and get the results by e-mail.

Visit www.annemergmed.com today to see what else is new online!